

Case Study

INDICATION

Both Column, Acetabular, and
Contralateral Rami Fractures
Case Study Treated with Acumed
Pelvic Plates

PRODUCTS

Anterior Brim Plate
Quadrilateral Surface Plate

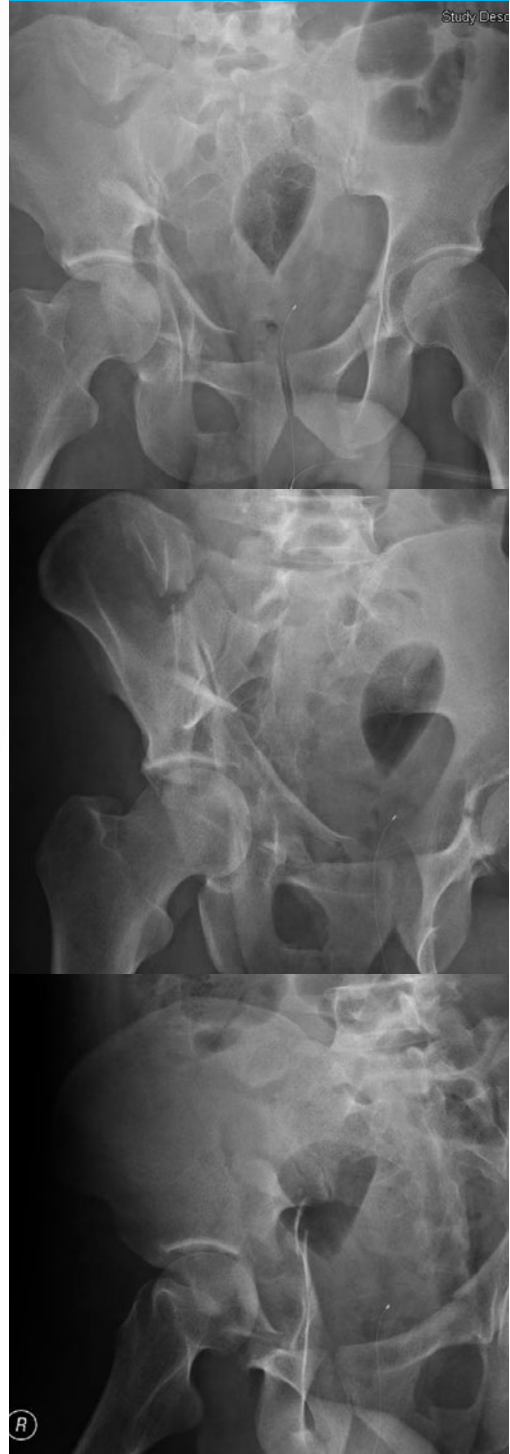

Case Study

Acumed® Pelvic Plating System

SURGEON

Charles N. Moon, M.D.



BACKGROUND

22 year old otherwise healthy male in a motor vehicle accident. No loss of consciousness, however there was a prolonged extraction. His GCS is 15 on arrival to ER. Trauma work up is only positive for an acetabular fracture. He is fluid resuscitated and thorough physical exam and radiographic evaluation is undertaken. Right both column acetabular fracture and contralateral rami fractures are identified. While the patient had dome coverage due to his young age and the disruption of his quadrilateral surface he was offered surgery to minimize risk of medial subluxation. Titanium precontoured plates were selected for multiple reasons:

- If the patient's hip fails, then there would be a minimized risk of metal dipole issues as most acetabular components and screws are also titanium.
- Removing medial acetabular hardware is something many hip replacement surgeons are unfamiliar with and dissecting through scarred tissues planes to remove medial hardware can be treacherous.
- The Pelvic brim and rami can be a relatively complex structure to contour to; a precontoured shape can often help by getting a surgeon more easily "in the ball park".

Preoperative X-rays

TREATMENT

Patient was anesthetized and positioned supine on a Profx fracture table. The ipsilateral hip was slightly flexed as was the knee to relax the iliopsoas and the sciatic nerve respectively. Traction was applied to distract the hip joint. Prior to prep and drape imaging was used to confirm proper distraction. The first window of the ilio inguinal approach and a modified stoppa approach were performed sequentially. Working through both of these approaches the fracture was reduced from proximal to distal. There was some instability from the contralateral rami fractures that were not addressed. The quadrilateral surface was quite comminuted and this was addressed with the quadrilateral surface buttress plate after the pelvic brim was reestablished and stabilized with a brim plate. Multi-planar fluoroscopic views were used to confirm proper reduction and plate positioning.

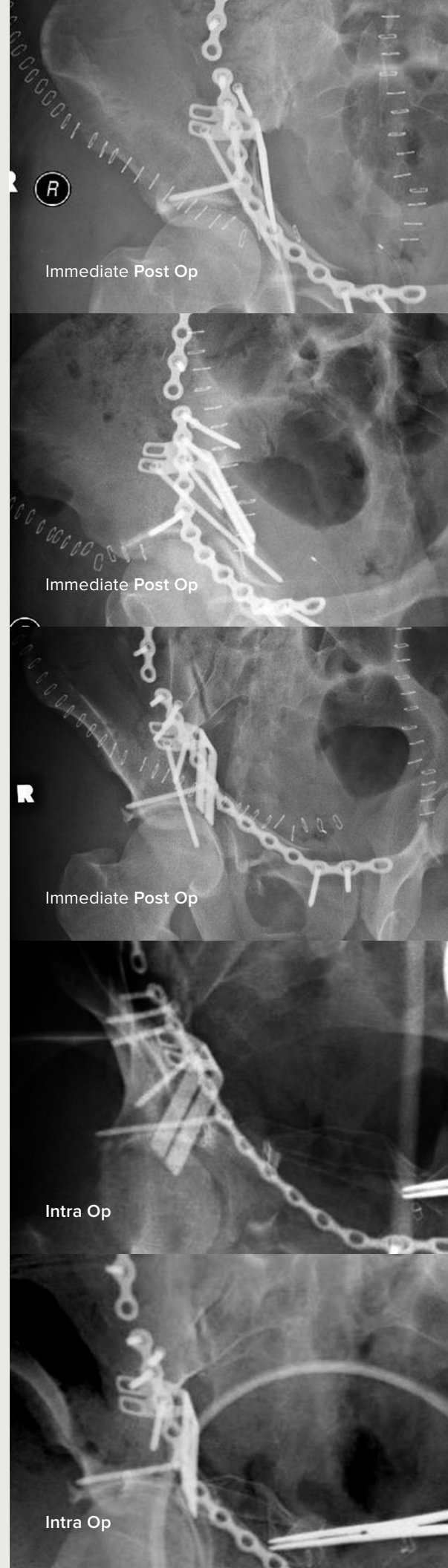
POSTOPERATIVE CARE

The patient was placed on mechanical and chemical DVT prophylaxis post operatively as well as getting appropriate perioperative antibiotics. Physical therapy was initiated post-op day one with the patient being allowed to be touch down weight bearing on the affected side. No range of motion restrictions were advised. After wounds were healed (after approximately two weeks) the patient was allowed pool therapy and weight bearing as tolerated in the pool with the water at chest level. Land therapy was restricted to touch down weight bearing for two months postoperatively. Patient was weaned off of narcotic pain medication. He initiated weight bearing as tolerated, however he is still using an assistive device. To date (Oct. 2013) long term follow up is still pending.

DISCUSSION

Titanium implants have been somewhat worrisome in the pelvis due to a relative amount of “flexibility” compared to their steel counterparts. However, in acetabular surgery, there is the benefit of not having concerns about “mixing metals” should the hip socket fail and the patient need to proceed to hip arthroplasty. Anterior approaches such as the ilio-inguinal and the modified Stoppa approach are workhorses for open reduction and internal fixation, however they are essentially never used as part of arthroplasty approaches. The fracture surgeon is often NOT the arthroplasty surgeon. Therefore familiarity with these approaches and experience in accessing the anterior/medial hardware is often lacking. Even if the hardware has been placed via a Kocher approach, it can be hard to get to through a scarred/socked down tissue bed with the sciatic nerve in the vicinity. It is advantageous to not have the common concerns about creating dipoles and other metal related issues in arthroplasty today.

Precontouring is also a benefit for anterior hardware in particular. While contouring pelvic plates is not necessarily overly onerous, minimizing bending time in the Operating Room means maximizing attention span and effort on more critical issues such as reduction.





TMA70-02-A

Effective: 12/2013

© 2013 Acumed® LLC

Acumed®
5885 NW Cornelius Pass Road
Hillsboro, OR 97124

Office: 888.627.9957
Fax: 503.520.9618
acumed.net

