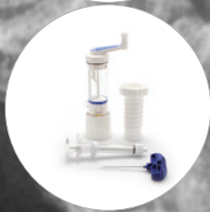



## Impacted Extra-articular Radius Fracture

### Case Study

#### Randy Bindra, MD

A 56-year-old female with an extra-articular distal radius fracture was treated with an Acu-Loc 2 plate and Callos Bone Void Filler.

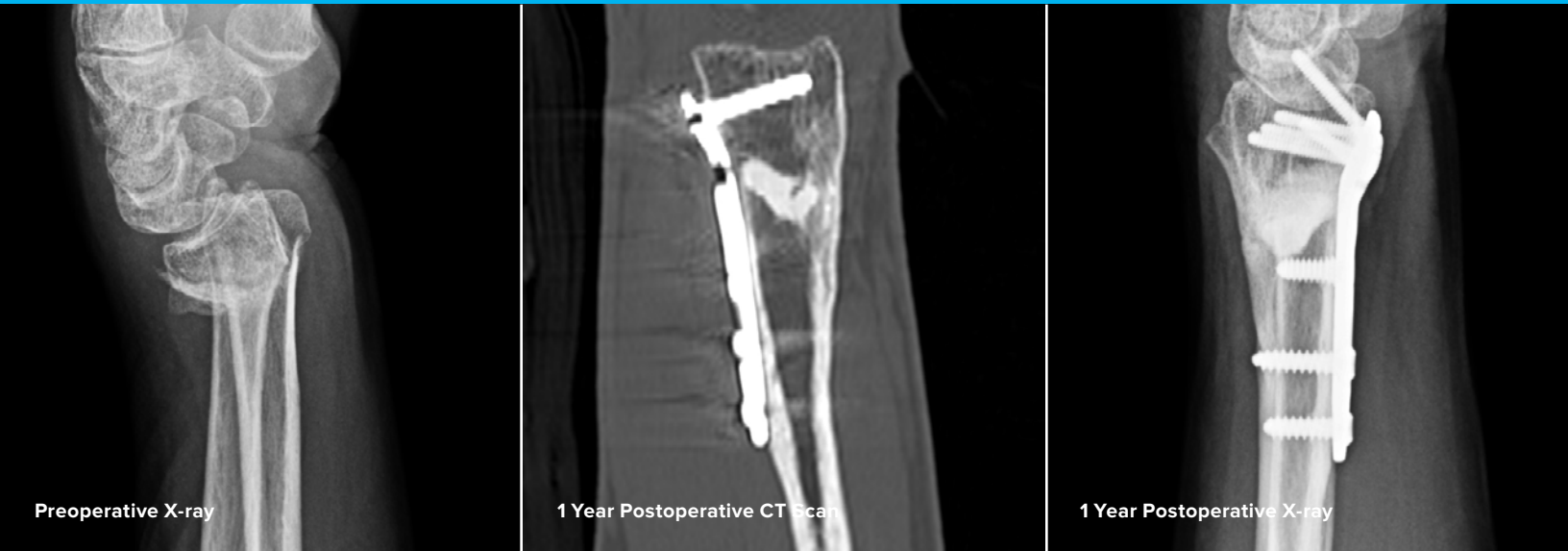

Acumed® is a global leader of innovative orthopaedic and medical solutions.



We are dedicated to developing products, service methods, and approaches that improve patient care.

## Case Study | Randy Bindra, MD



## Impacted Extra-articular Radius Fracture

### Patient History

A 56-year-old left hand dominant female slipped on ice on the sidewalk and fell onto her left wrist 6 weeks prior to presentation. She sustained an extra-articular distal radius fracture that was initially casted after closed reduction at an outside facility. The fracture collapsed while in the cast with recurrence of the initial deformity and the patient presented for a second opinion. In addition to the “dinner-fork” deformity, her radiographs demonstrated 12 mm shortening and 30 degrees of dorsal angulation of the distal radius. The patient was offered surgery for reduction and fixation of the fracture. It was anticipated that there would be a metaphyseal void in the radius after correction of the deformity.

## Treatment

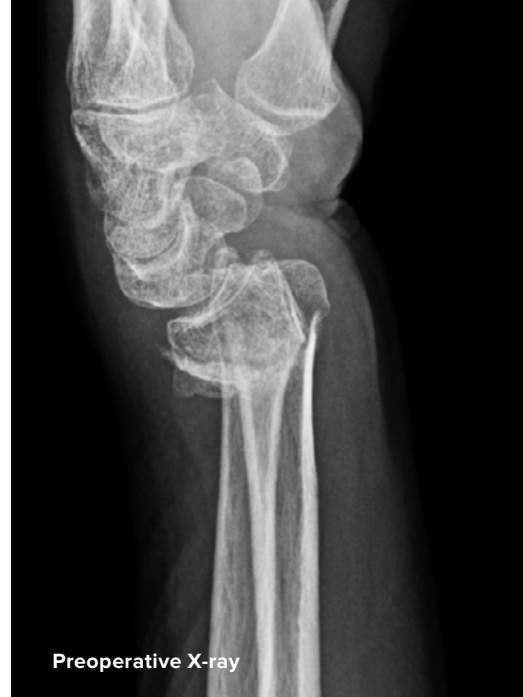At surgery, soft tissue release was followed by fixation of the Acu-Loc® 2 plate to the distal fragment with locking screws. Volar tilt was restored as the plate was clamped to the radial shaft. A “push-pull” screw was placed in the radius cortex proximal to the plate for placement of a lamina spreader for gradual distraction and restoration of radius height. After fixation to the shaft was completed, Callos® Impact bone void filler putty was mixed and carefully packed into the 9 x 9 x 22 mm metaphyseal void.

## Postoperative Care

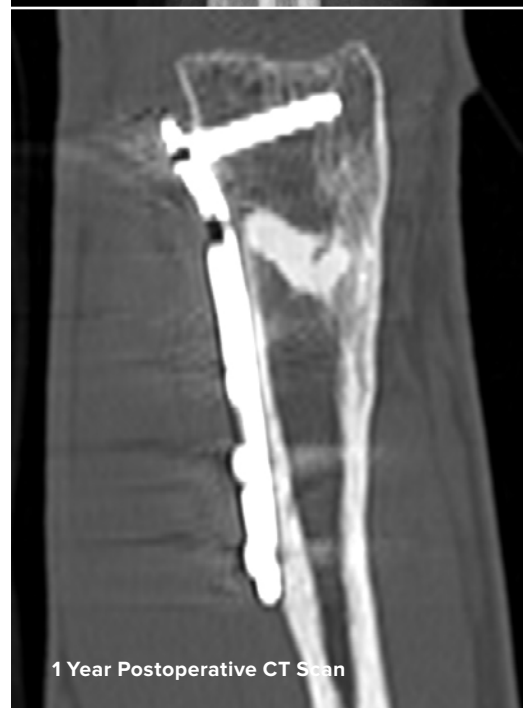The patient was allowed to start wrist and hand rehabilitation with a removable splint two weeks after surgery. The patient regained full range of motion of her left wrist three months post operatively. The patient subsequently returned a year later with symptoms of hand numbness. Carpal Tunnel Syndrome was diagnosed and surgery was offered. The patient requested removal of the radius plate implant at the time of her carpal tunnel release. X-rays demonstrated healing of the distal radius fracture with anatomical alignment and remodeling and partial incorporation of the Callos. A CT scan was performed to confirm bony integrity and demonstrated abundant bony bridging all around the Callos and cancellous bone ingrowth into the Callos. The device explantation and carpal tunnel release were uneventful. There was no soft tissue inflammation or foreign body reaction around the plate or Callos and the visible Callos was well integrated in the radius metaphysis.

## Discussion

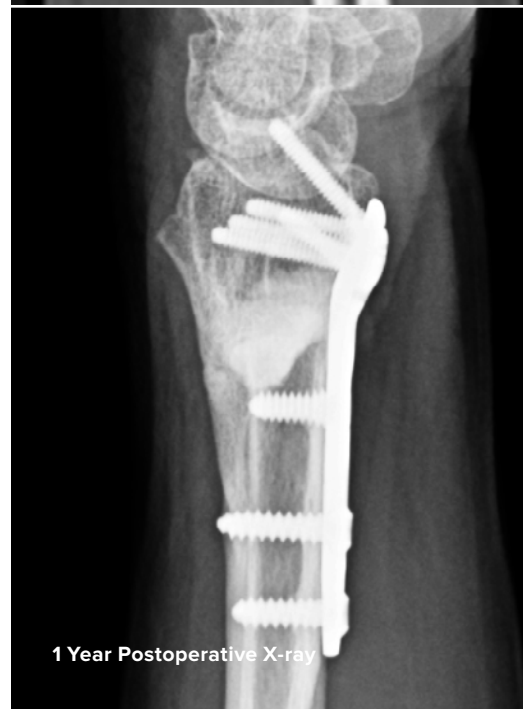Callos remodels like normal bone with gradual resorption by osteoclastic activity and ingrowth of trabecular bone. Callos is especially advantageous in filling bone voids around metaphyseal fractures with locked plate fixation to prevent metaphyseal collapse during the initial phase of rehabilitation.



Preoperative X-ray



1 Year Postoperative CT Scan



1 Year Postoperative X-ray



BIO70-08-B

Effective: 2018/03

© 2018 Acumed® LLC

Acumed® Headquarters  
5885 NE Cornelius Pass Road  
Hillsboro, OR 97124  
Office: 888.627.9957  
Fax: 503.520.9618  
www.acumed.net

These materials contain information about products that may or may not be available in any particular country or may be available under different trademarks in different countries. The products may be approved or cleared by governmental regulatory organizations for sale or use with different indications or restrictions in different countries. Products may not be approved for use in all countries. Nothing contained on these materials should be construed as a promotion or solicitation for any product or for the use of any product in a particular way which is not authorized under the laws and regulations of the country where the reader is located. Specific questions physicians may have about the availability and use of the products described on these materials should be directed to their particular authorized Acumed distributor. Specific questions patients may have about the use of the products described in these materials or the appropriateness for their own conditions should be directed to their own physician.

Acumed® and Acu-Loc® 2 are registered trademarks of Acumed LLC

Callos® is a registered trademark of and is manufactured by Skeletal Kinetics LLC

