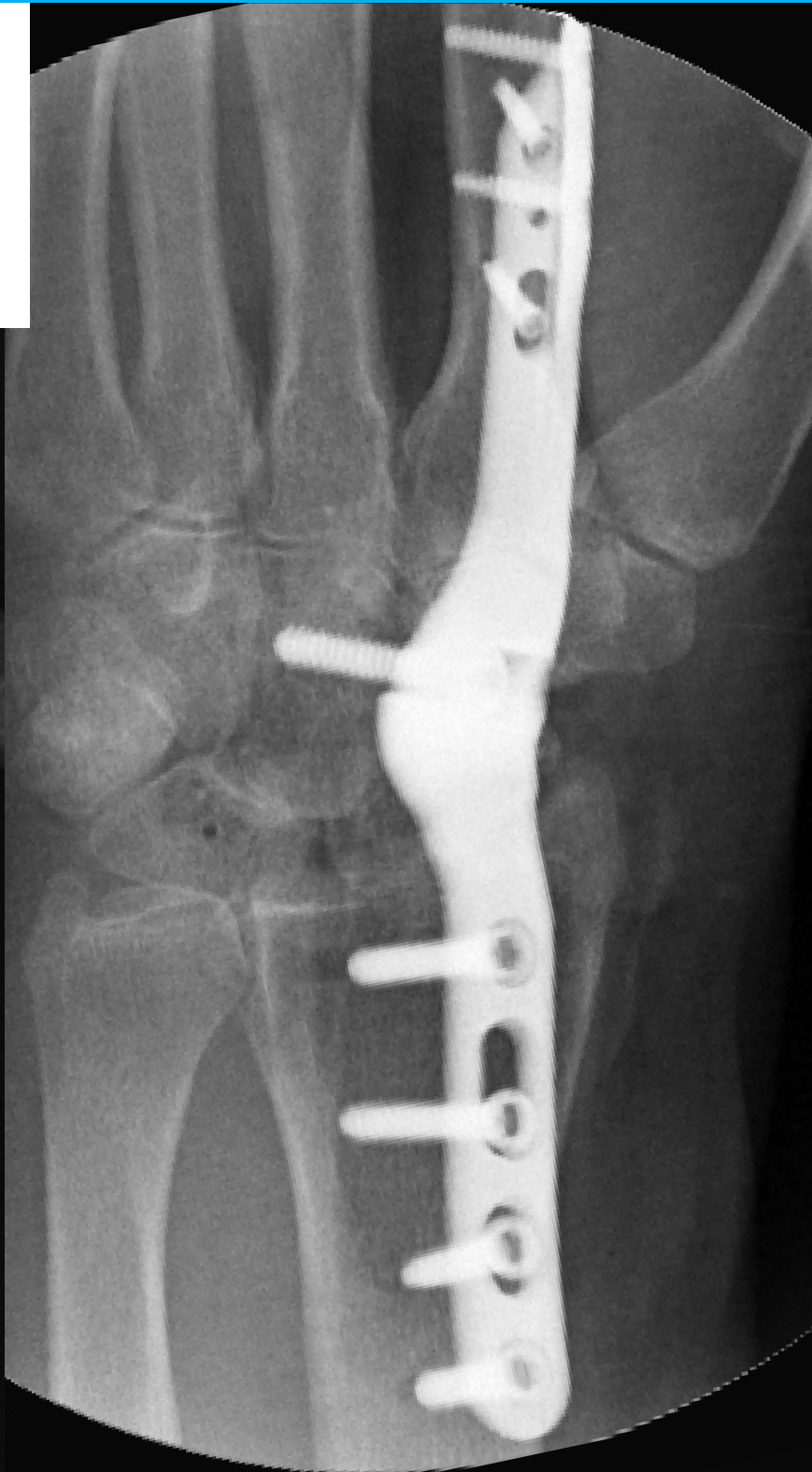
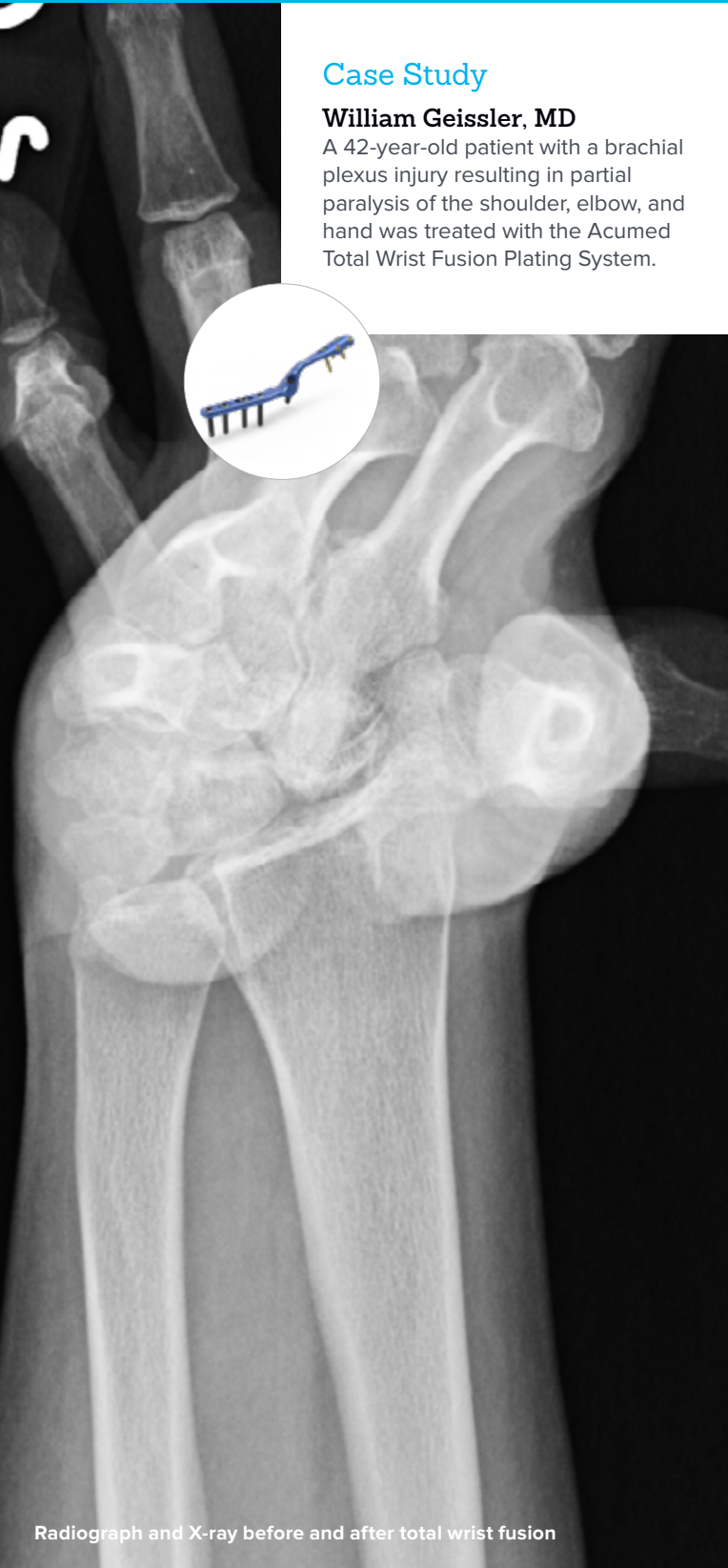
## Improving Hand Function Following Brachial Plexus Injury

### Case Study

#### William Geissler, MD

A 42-year-old patient with a brachial plexus injury resulting in partial paralysis of the shoulder, elbow, and hand was treated with the Acumed Total Wrist Fusion Plating System.

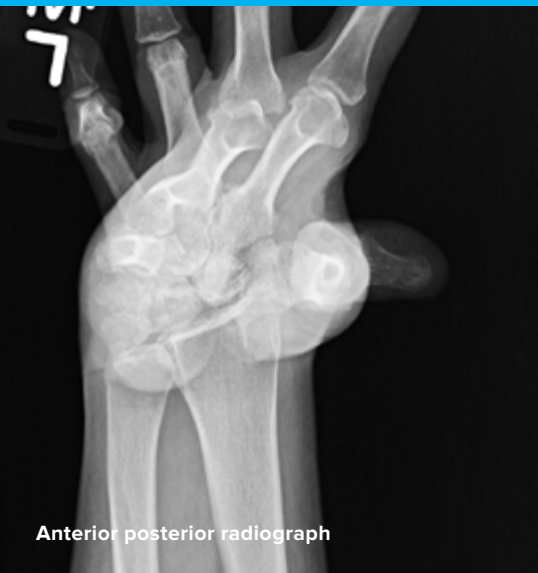

Acumed® is a global leader of innovative orthopaedic and medical solutions.

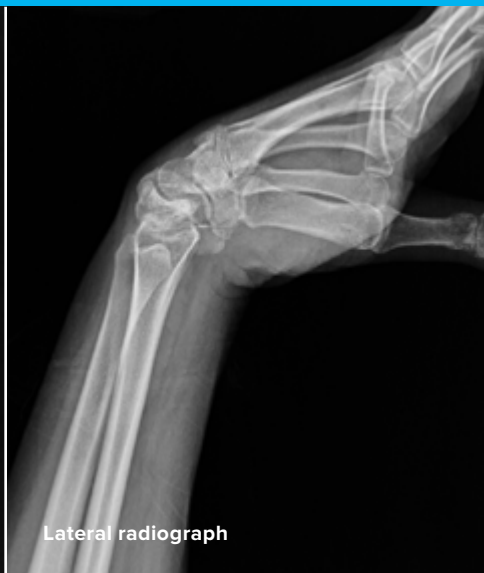

We are dedicated to developing products, service methods, and approaches that improve patient care.

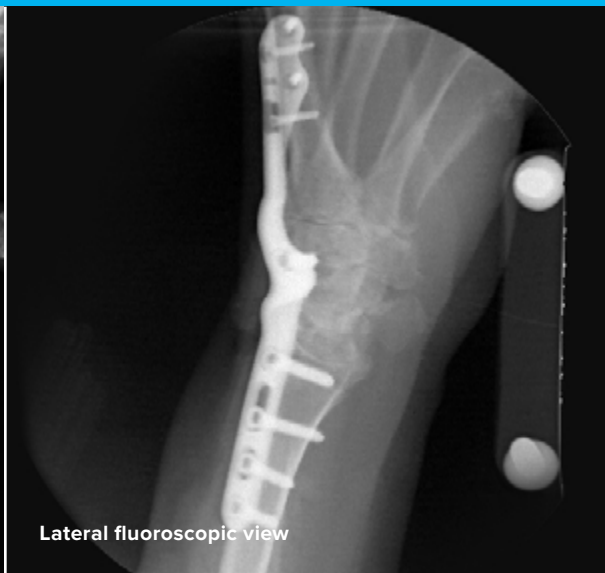## Case Study | William Geissler, MD



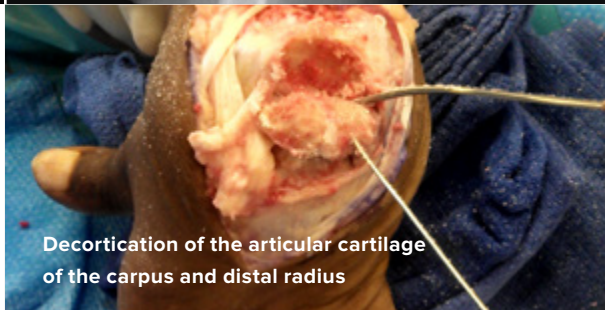
Anterior posterior radiograph



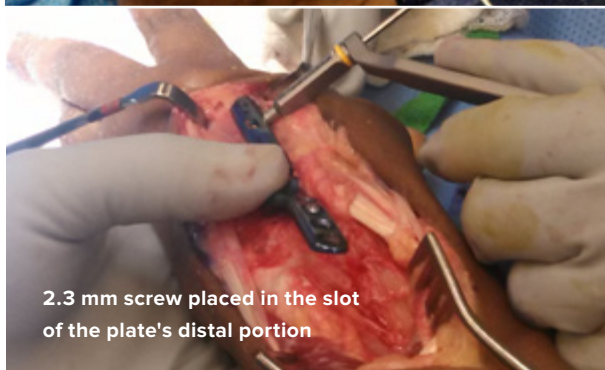
Lateral radiograph



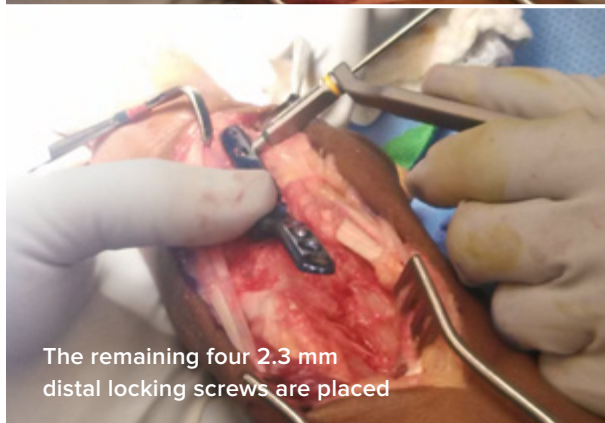
Lateral fluoroscopic view



Decortication of the articular cartilage of the carpus and distal radius



2.3 mm screw placed in the slot of the plate's distal portion



The remaining four 2.3 mm distal locking screws are placed

## Improving Hand Function Following Brachial Plexus Injury

### Patient History

The patient is a 42-year-old male who sustained a brachial plexus injury several years ago. This resulted in a partial paralysis of the shoulder, elbow, and hand.

The patient had weak but active shoulder flexion and abduction, as well as elbow flexion and extension. The patient also had weak intact finger flexion, but the wrist was in a flexed position. The patient had extensive physical therapy, as well as Botox injections and dynamic extension bracing.

The patient desired fusion of the wrist in extension to attempt to put the hand in a more functional position and to also potentially improve his finger function, which was limited but intact. Options discussed were proximal row carpectomy and fusion, which would result in shortening of the wrist that may have further weakened his finger flexion, or fusion of the wrist while maintaining length. The patient opted to keep the wrist out to length in order to obtain the maximum grip strength.



## Treatment

A standard dorsal approach to the wrist was made. The extensor pollicis longus was identified and released in the third compartment and retracted radially. The interval between the second and fourth compartments was sharply opened. The extensor digitorum communis tendons were retracted ulnarly and the wrist extensor tendons were retracted radially. A radial-based dorsal capsular flap was then made, exposing the carpus.

It is extremely important to do a thorough decortication of the carpal bones in the radial and mid-carpal rows, as well the articular surface of the distal radius. I have seen a number of wrist fusion nonunions where the articular cartilage of the carpus was minimally decorticated. In this case, the articular cartilage was completely removed from the radial-carpal and mid-carpal rows to expose the cancellous bone as well as the distal radius. It is the author's personal opinion that adding demineralized bone matrix at the fusion site may help the wrist fusion to unite.

The Acumed wrist fusion set has five plates, four of which are left or right specific, designed to fit on the dorsum of the index metacarpal. The plate is designed to sit away from the extensor digitorum tendons to reduce tendon irritation compared to a standard straight dorsal plate. A neutral plate is designed to fit on the third metacarpal when a proximal row carpectomy is performed in addition to the wrist fusion.

The extensor carpi radialis longus tendon was released for a better fit for the plate on the index metacarpal. The extensor carpi radialis brevis tendon may or may not be released depending on the surgeon's preference and how the plate fits. The plate was designed to be initially placed on the second (index) metacarpal.

The wrist fusion plate was placed along the index metacarpal and a 2.3 mm screw was inserted into the slot of the distal screw hole in the plate. This compressed the plate down to the dorsal radial aspect of the index metacarpal. The remaining converging screws were placed in the distal end of the plate.

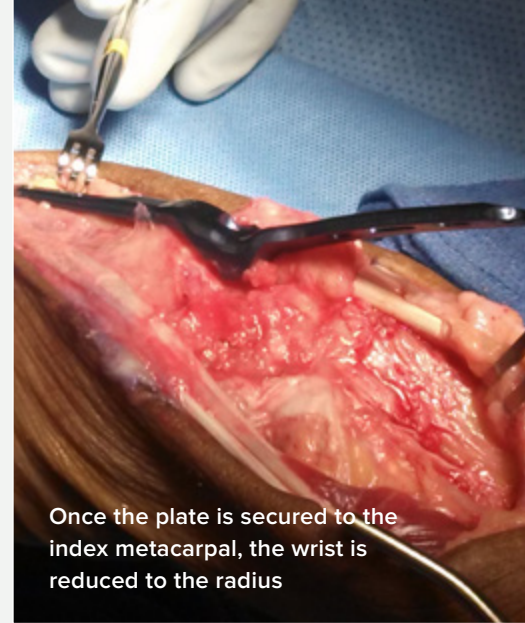
Once the plate was secured to the index metacarpal, the plate and the carpus were reduced to the distal radius. The plate placement is just radial to the dorsal most prominent portion of the distal radius, and is intended to decrease as much extensor tendon irritation as possible. The first screw placed was a 3.5 mm nonlocking screw in the slot as the wrist was held reduced and compressed. A second 3.5 mm nonlocking screw was then placed in the offset screw hole to further compress the fusion site. The two remaining 3.5 mm locking screws were placed in the plate in the distal radius.

The last screw placed was the 3.5 mm locking screw in the carpal, which was aimed into the capitate from an oblique angle. It is important not to plunge when drilling this screw hole so as not to affect the ulnar neurovascular bundle. The purpose of this screw is to decrease as much micromotion as possible between the index metacarpal and trapezoid joint.

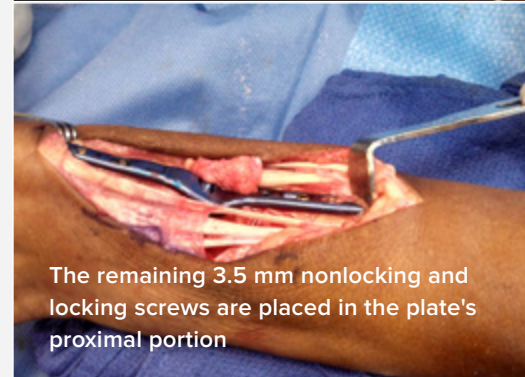
The dorsal capsule was closed over the plate in an attempt to avoid extensor tendon irritation. As seen in the images, the extensor tendons lie away from the plate and do not make contact. The retinaculum of the second and fourth dorsal compartments were closed to secure the remaining extensor digitorum tendons. The extensor pollicis longus tendon was left free.

## Postoperative Care

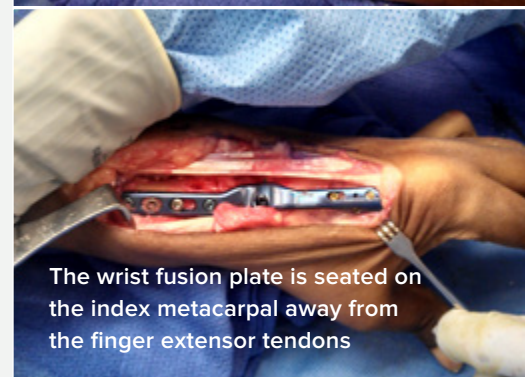Postoperatively, digital range of motion exercises were started immediately. Strengthening exercises were started approximately two weeks postoperatively when the sutures were removed.



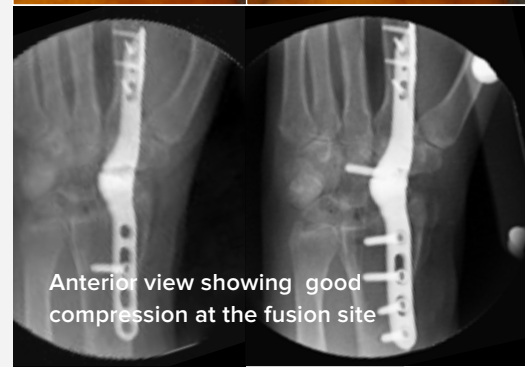
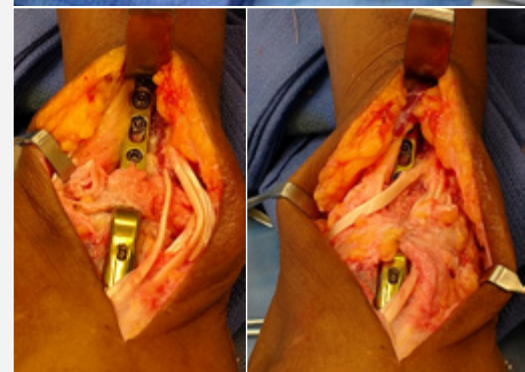
Once the plate is secured to the index metacarpal, the wrist is reduced to the radius



The remaining 3.5 mm nonlocking and locking screws are placed in the plate's proximal portion



The wrist fusion plate is seated on the index metacarpal away from the finger extensor tendons



Anterior view showing good compression at the fusion site



**HNW70-21-A**

Effective: 2018/10

© 2018 Acumed® LLC

Acumed® Headquarters  
5885 NE Cornelius Pass Road  
Hillsboro, OR 97124  
Office: 888.627.9957  
Fax: 503.520.9618  
[www.acumed.net](http://www.acumed.net)

These materials contain information about products that may or may not be available in any particular country or may be available under different trademarks in different countries. The products may be approved or cleared by governmental regulatory organizations for sale or use with different indications or restrictions in different countries. Products may not be approved for use in all countries. Nothing contained on these materials should be construed as a promotion or solicitation for any product or for the use of any product in a particular way which is not authorized under the laws and regulations of the country where the reader is located. Specific questions physicians may have about the availability and use of the products described on these materials should be directed to their particular authorized Acumed distributor. Specific questions patients may have about the use of the products described in these materials or the appropriateness for their own conditions should be directed to their own physician.

