

## Case Study:

Use of the InFrame™ Intramedullary Threaded Micro Nail for an Oblique, Comminuted Fracture of the 5<sup>th</sup> Proximal Phalanx

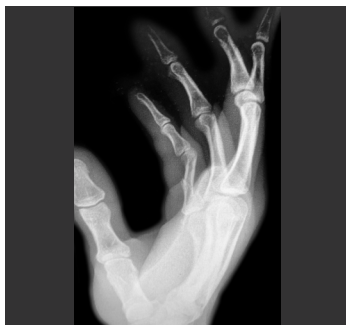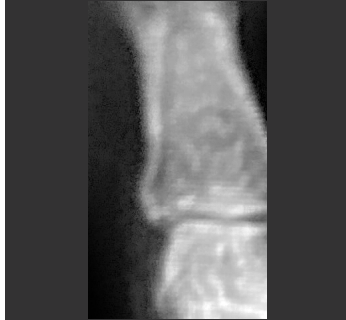---



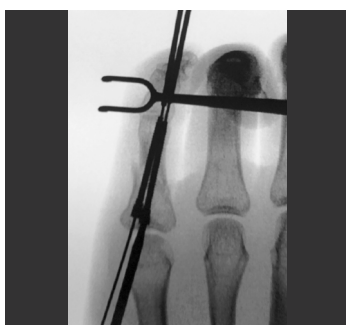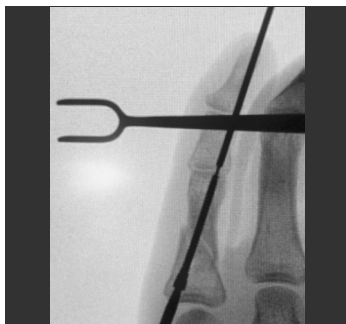Lloyd Champagne, MD

Arizona Center for Hand to Shoulder Surgery  
Phoenix, AZ

Pre-op



Intra-op



## Case Presentation

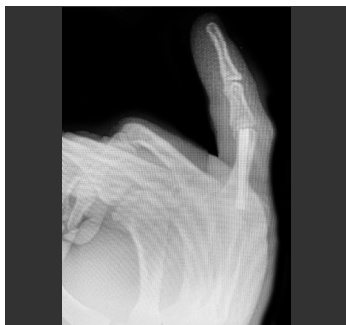
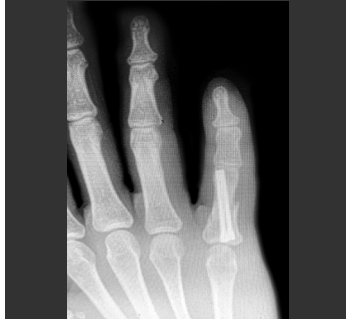Patient was a 24-year-old male who suffered a midshaft oblique fracture to his 5<sup>th</sup> proximal phalanx from a high impact injury. Rigid fixation with rotational stability was desired to allow immediate range of motion (ROM) and resumption of daily activities.

## Pre-op Plan

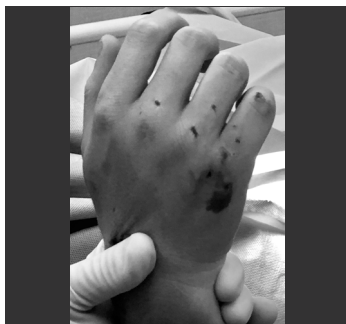K-wires were considered but result in poor fixation, do not allow for immediate mobilization, and are associated with high complication rates. Other common issues with this approach are pin site infections, poor range of motion outcomes, and the need for a secondary removal surgery. Although plates and screws achieve rigid fixation, the approach is tedious, time consuming, requires large surgical exposure, and is associated with poor range of motion outcomes. Dr. Champagne also considered headless compression screws (HCSs) as an intramedullary approach but the available diameter and length offerings did not permit flexible construct patterns that are necessary for rotational control or achieve complete proximal to distal bi-cortical purchase in larger phalanges, respectively. Also, available headless compression screws can cause angular deformities as the screws compress during insertion.

Dr. Champagne chose InFrame because the cannulated, fully threaded micro nail can be easily placed in the proximal phalanx through an open or percutaneous, intramedullary approach. The 2.0mm diameter design allows various implantation constructs, satisfying almost any fracture pattern, including comminuted phalangeal fractures, while enhancing rotational stability and bi-cortical bone purchase. The unique dual diameter guidewire removes the need for reaming and allows the micro nail to be inserted over the trailing end of the guidewire accurately and efficiently. Biomechanical testing has demonstrated the superior rigidity with InFrame compared to K-wires and plates, allowing immediate active range of motion and reduced recovery time.

Post-op



PACU



## Operative Findings and Approach

Although the fracture was seven days old, Dr. Champagne was able to anatomically reduce the fracture using a closed, percutaneous approach with InFrame. First, he inserted the dual diameter guidewire across the fracture site under fluoroscope to stabilize the fracture and accurately align the desired final implant position. Next, Dr. Champagne used the depth gauge to determine that a 28mm micro nail was needed for the 5<sup>th</sup> proximal phalanx. The larger diameter of the guidewire was used to push the guidewire distally until the smaller diameter was across the fracture. He then threaded the cannulated InFrame micro nail until bi-cortical purchase was achieved at both the distal and proximal ends. Once he verified the final position of the first implant under fluoroscope, Dr. Champagne used the same methodology to place the second InFrame micro nail but with a trajectory in a different plane from the first implant to create rotational stability. Due to the limited intramedullary space, Dr. Champagne created an “A” configuration with the two InFrame implants that slightly crossed distally. Total surgery time was approximately 10 minutes.

## Follow-up

With only 5 minutes of physician directed “therapy,” the patient achieved full range of motion in the recovery room. Band-Aids were placed as dressings and the patient resumed full unrestricted activities the following day, which would have been difficult, if not impossible, to replicate with other fixation techniques or implants.

## Discussion

The use of InFrame allowed Dr. Champagne to percutaneously address the proximal phalanx fracture with an “A” frame construct, providing cortex to cortex stability with rotational control, in only 10 minutes of total surgery time. InFrame has a robust length offering that allows for various construct patterns in the phalanx, which on average are 5 cm in length.

Bi-cortical, threaded fixation with rotational stability allows for immediate range of motion (only restriction may be heavy lifting activities). The delivery mechanism for InFrame is also important because it simplifies the implant placement. The innovative dual diameter guidewire removes the need for a dedicated reamer and allows the accurate placement of multiple vectors, personalizing the construct based on each patient's individual fracture pattern. The implant does not require additional resources, and follow-ups are typically easy and straight-forward because patients often do not need formal therapy, as mobilization is immediate. This allows patients to minimize their downtime and return to work or daily activities faster than other implants and surgical approaches.